



2007 7 REVEAL PAH [11]

[1] AMBITION [12]

2003 3 PAH

arterial hypertension PAH pulmonary 11 4 5 6
2008 2013 2018

11 PAH CAV-1 2016 ESC
KCNK3 TBX4 EIF2AK4 BMP9 [2-6] ERS [7]

PAH 2007

PAH 2007

PAH [7] 2007

chronic thromboembolic 2007
pulmonary hypertension, CTEPH [8]

CTEPH

optical coherence tomography, OCT 11 2007
/ Pd/Pa [9] CTEPH

CTEPH /

EARLY
World Health Organization, WHO [10]

/ / arterial hypertension, IPAH

PAH

A

pulmonary hypertension pulmonary arterial hypertension idiopathic pulmonary arterial hypertension

B

C

/

pulmonary hypertension pulmonary arterial hypertension

2007

1

pulmonary embolism

[13]

2

pulmonary hypertension

1

mean pulmonary artery pressure, mPAP 25 mmHg
1 mmHg=0.133 kPa [7] mPAP 14±3
mmHg 20mmHg
PAH

2018 6
2

PAH

mPAP 25 mmHg pulmonary 1% >
artery wedge pressure, PAWP 15 mmHg 65 10%
>3 Wood [7] /
idiopathic pulmonary [14] 80%

mPAP 25 mmHg
mPAP 25 mmHg PAWP 15 mmHg
PVR>3 Wood /

mPAP 25 mmHg PAWP>15 mmHg
DPG<7 mmHg / PVR 3 Wood
DPG 7 mmHg / PVR>3 Wood

mPAP PAWP PVR DPG dPAP DPG=dPAP-
PAWP 1 mmHg=0.133 kPa

1.1	PAH		31
1.2		PAH	32
1.3	PAH		33 /
1.4		PAH	34
1.5		PAH	35
1.5.1			
1.5.2		HIV	4.1 CTEPH
1.5.3			4.2
1.5.4			4.2.1
1.5.5			4.2.2
1.6		PVOD / PCH	4.2.3
1.7		PPHN	4.2.4
			4.2.5
			4.2.6
21		HFrEF	5.1
22		HFrEF	5.2
23			5.3
24			

PAH 2011 IPAH 1 3
 5~10/ 15~60/ 92.1% 75.1%

[15] IPAH PAH [22]

PAH PAH

2/3^[16] IPAH PAH 50~65 PAH
 20 80 36 [17]

PAH 1 3 5 68%

48% 34%^[18] 20 90 PAH 3^[7]

2006 IPAH

PAH PAH 1

89.3%^[16] 2010

IPAH PAH PAH 1

2 3 89% 68% 55%^[19]

PAH [20]

PAH IPAH

PAH PAH

IPAH [21] PAH /

2006 PAH IPAH

PAH 1 3 5 68.0% /

38.9% 20.8%^[21] 2007

PAH ACVRL1 ENG
71%

DNA [32] PAH

RNA [23] [nitric oxide, NO] [24-25] IPAH PAH

[MAPK

Rho/ROCK PI3K/AKT PAH

BMP / TGF- Notch] [22-23 26-27]

B NF B

PVOD PCH EIF2AK4 [5] PAH IPAH PAH

PVOD/PCH 9%~25% EIF2AK4 [33]

PAH PVOD/PCH PAH IPAH

PAH 9 EIF2AK4 PVOD/PCH PVOD/PCH Sanger

SMAD9 BMPR1B TBX4 CAV1 KCNK3 BMPR2 BMP9 ACVRL1 ENG

50%~80% PAH 20%~50%

IPAH [7,28]

BMPR2 PAH IPAH

20%~40% IPAH 70%~80% PAH

[29] BMPR2 PAH

IPAH 53% 15% [30] BMPR2

PAH 7.5%

12.3% [31] BMPR2 PAH 20%

14%

42% [28] BMPR2

IPAH/ PAH [29-30] [34-35] CTEPH


BMP9 IPAH [6] BMP9


IPAH 22 6.7%

IPAH BMP9 [36]

BMPR2 2 IPAH

PAH





1.0 3~4 / 8
>1 CT
PVOD/PCH PVOD CT

[51]

PCH CT 9.

1/3 PAH

CT

/

CTEPH

CTEPH
CT

CT
[49]

CT

CTEPH

CT

S

C

CT

NT-proBNP BNP

10.

7.

IPAH

[7]

[50]

Abemethy

CT

IPAH

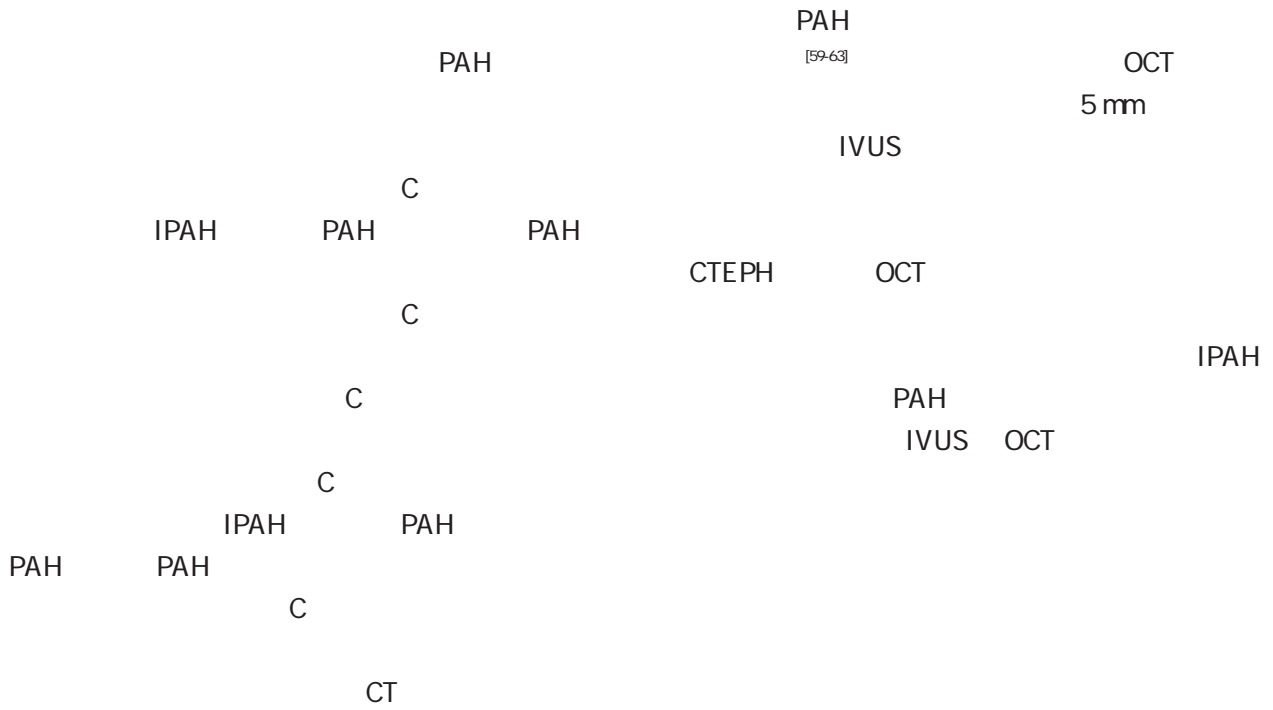
11.

æ N ó z

% gL#%æ N ó z

1

1



/

30° ~60°
 30° ~60°
 30° ~60°
 60° 30° ~

[58]

ultrasound, IVUS
 coherence tomography, OCT

intravenous
 optical

a C
CTEPH

CT

a C

3

6

5

3-6
[72]

PAH

PAH

PAH

1 C

PAH

PAH

C

3-6

PAH

C

a C

5

/

6

1/4

WHO

60mmHg

2000m

1.

IPAH

PAH

CTEPH

[75]

PAH

<85%

<

1 500-

1.


IPAH

[73]

2

[74]

2



WHO
[101-103]

PAH

PAH

70%^[104]

2-4 ng kg

%

PAH

	PAH	625-125 mg	2	2 mg kg ⁻¹ d ⁻¹	2
	PAH	5-10 mg	1	1.25-2.5 mg	1
	PAH	10 mg	1		
5		20-80 mg	3	<1	0.5-1 mg
		kg ⁻¹ d ⁻¹ 3		<20 kg 10 mg	3
		20 kg 20 mg	3		>
		40 mg	1	10-20 mg	1
		25-10 mg	1		
		5-10 mg	2	1.25-2.5 mg	2
	PAH CTEPH	1 mg	3	25 mg	3
	PAH	2-4 ng kg ⁻¹ min ⁻¹		100 ng kg ⁻¹ min ⁻¹	20-40
	PAH	ng kg ⁻¹ min ⁻¹		ž	
	PAH				
IP	PAH				

<60%

PAH CTEPH

PAH

CTEPH 6

IPAH 3 23% 2.8%^[125] IPAH 6

9% 15.8%^[38]

1/3 PAH

[119] ECMO PAH

3 1 5

93% 90% 87%^[120] PAH

18 IPAH

1 3 77.8%

72.2%^[121] PAH CTEPH

[122-123]

PAH

1%~6%^[7]

9

WHO

ICU

<90mmHg >110 /min

CT

PAH

1.

PAH PAH

132

PAH 8%

[124]

231 PAH

PAH

5%~10%^[126]

PAH PAH
2 PAH
1 4

2

3 PAH
IPAH
4 PAH
PAH
3 PAH
PAH

PAH

/

[7,127-128]

PAH

[129]

PAH PAH PAH
PAH PAH PAH

PAH

PAH

PAH

PAH

1

2

3

PAH

1

2

PAH

PAH

/

ESSDAI

PAH

PAH

PAH

3

PAH

PAH

1

physician global assessment (PGA) < 1

2 PAH

2015 CSTAR

/

PAH

[139]

PAH

PAH

Child-Pugh

B C

4.
 IPAHA REVEAL
 2 5
 67% 40%^[144]

10%
 PAH
 2
 5%

PAH^[145]
 [7] PAH PAH

85.9%^[146]
 PAH PAH
 [147] 3

[148] 10 PAH
 \$

HIV
 HIV PAH HIV
 PAH 0.46%

IPAHA 2 500 PAH
 HIV PAH PAH 2%~
 7%^[149] HIV HIV
 PAH 1995 0.21% 2006
 0.03% [150]

>3
362 PAH 88% IPAH/
PAH PAH
57% 36%^[159]
10
IPAH/ PAH 2
5 90% 75%^[158]

WHO
2011
PVRI
10
PAH [160] IPAH
PAH
2

[167]

PAWP HFpEF
PAWP <15 mmHg^[168]

CTEPH	[179-180]	3		2.2%~3.5%
CT			5	82% 10
PAH		3		75% ^[183]
CTEPH				
CTEPH		10		CTEPH
				[184-186]
				CTEPH
<hr/>				
0			5	95%
<hr/>				
	CTEPH	PAH		
	PAH			
			/	
	CTEPH		[8]	PAH
MERIT		CTEPH		
	PAH			
CTEPH		[181]		
		CTEPH		
				CTEPH
	CTEPH		56.8%	
		[182]		
	1			
	2			
	3			

- [1] [J].
, 2007, 35(11): 979-987. DOI: 10.3760/j.issn:0253-3758.2007.11.002
- [2] Austin ED, Ma L, LeDuc C, et al. Whole exome sequencing to identify a novel gene (cavedin 1) associated with human pulmonary arterial hypertension[J]. *Circ Cardiovasc Genet*, 2012, 5(3):336-343. DOI: 10.1161/CIRCGENETICS.111.961888
- [3] Ma L, Roman Campos D, Austin ED, et al. A novel channelopathy in pulmonary arterial hypertension[J]. *N Engl J Med*, 2013, 369(4):351-361. DOI: 10.1056/NEJMoa1211097.
- [4] Kerstjens-Frederikse WS, Bongers EM, Roofthoofit MF, et al. TBX4 mutations (small patella syndrome) are associated with childhood onset pulmonary arterial hypertension[J]. *J Med Genet*, 2013, 50(8): 500-506. DOI: 10.1136/jmedgenet-2012-101152
- [5] Eyries M, Montani D, Girerd B, et al. EIF2AK4 mutations cause pulmonary veno-occlusive disease, a recessive form of pulmonary hypertension[J]. *Nat Genet*, 2014, 46(1): 65 - 69. DOI: 10.1038/ng.2844.
- [6] Wang XJ, Jiang X, Lian TY, et al. Germline BMP9 mutation causes idiopathic pulmonary arterial hypertension[J]. *Eur Respir J*, 2018, In press.
- [7] Galiè N, Humbert M, Vachiery JL, et al. 2015 ESC /ERS Guidelines for the diagnosis and treatment of pulmonary hypertension: the Joint Task Force for the Diagnosis and Treatment of Pulmonary Hypertension of the European Society of Cardiology (ESC) and the European Respiratory Society (ERS): endorsed by: Association for European Paediatric and Congenital Cardiology (AEPC), International Society for Heart and Lung Transplantation (ISHLT)[J]. *Eur Heart J*, 2016, 37(1): 67-119. DOI: 10.1093/eurheartj/ehv317.
- [8] Ghofrani HA, D Armini AM, Grimminger F, et al. Riociguat for the treatment of chronic thromboembolic pulmonary hypertension[J]. *N Engl J Med*, 2013, 369(4): 319-329. DOI: 10.1056/NEJMoa1209657.
- [9] Mizoguchi H, Ogawa A, Munemasa M, et al. Refined balloon

monocrotaline pulmonary hypertension via NO, prostacyclin and endothelin-1 pathways[J]. *Eur Respir J*, 2013,41(5):1116-1125. DOI: 10.1183/09031936.00044112

- [26] Cai Z, Li J, Zhuang Q, et al. MR 125a 5p ameliorates monocrotaline induced pulmonary arterial hypertension by targeting the TGF β 1 and IL 6/STAT3 signaling pathways[J]. *Exp Mol Med*, 2018,

- 10.1093/eurheartj/ehq170
- [56] Jing ZC, Jiang X, Han ZY, et al. Ilprost for pulmonary vasodilator testing in idiopathic pulmonary arterial hypertension[J]. *Eur Respir J*, 2009, 33(6): 1354-1360. DOI: 10.1183/09031936.00169608
- [57] Zuo XR, Zhang R, Jiang X, et al. Usefulness of intravenous adenosine in idiopathic pulmonary arterial hypertension as a screening agent for identifying long term responders to calcium channel blockers[J]. *Am J Cardiol*, 2012, 109(12): 1801-1806. DOI: 10.1016/j.amjcard.2012.02.026
- [58] Hofmann LV, Lee DS, Gupta A, et al. Safety and hemodynamic effects of pulmonary angiography in patients with pulmonary hypertension: 10-year single-center experience [J]. *AJR Am J Roentgenol*, 2004, 183(3): 779 - 786. DOI: 10.2214/ajr.183.3.1830779.
- [59] Shen JY, Cai ZY, Sun LY, et al. The application of intravascular ultrasound to evaluate pulmonary vascular properties and mortality in patients with pulmonary arterial hypertension[J]. *J Am Soc Echocardiogr*, 2016, 29(2): 103-111. DOI: 10.1016/j.echo.2015.08.018
- [60] Ploegstra MJ, JGM B, Roos-Hesselink JW, et al. Pulmonary arterial stiffness indices assessed by intravascular ultrasound in children with early pulmonary vascular disease: prediction of advanced disease and mortality during 20-year follow-up[J]. *Eur Heart J Cardiovasc Imaging*, 2018, 19(2): 216-224. DOI: 10.1093/ehjci/jex015.
- [61] Inohara T, Kawakami T, Kataoka M et al. Lesion morphological classification by OCT to predict therapeutic efficacy after balloon pulmonary angioplasty in CTEPH[J]. *Int J Cardiol*, 2015, 197:23-25. DOI: 10.1016/j.ijcard.2015.06.036
- [62] Jiang X, Peng FH, Liu QQ, et al. Optical coherence tomography for hypertensive pulmonary vasculature[J]. *Int J Cardiol*, 2016, 222:494-498. DOI: 10.1016/j.ijcard.2016.07.215
- [63] Ishiguro H, Kataoka M, Inami T, et al. Diversity of lesion morphology in CTEPH analyzed by OCT, pressure wire, and angiography[J]. *JACC Cardiovasc Imaging*, 2016, 9(3): 324-325. DOI: 10.1016/j.jcmg.2015.02.015
- [64] Barst RJ, Chung L, Zamanian RT, et al. Functional class improvement and 3 year survival outcomes in patients with pulmonary arterial hypertension in the REVEAL Registry[J]. *Chest*, 2013, 144(1): 160-168. DOI: 10.1378/chest.12-2417.
- [65] [J]. , 2006, 34(4): 381 - 384. DOI: 10.3760/cma.j.issn.0253-3758.2006.04.032
- [66] ATS statement: guidelines for the six-minute walk test[J]. *Am J Respir Crit Care Med*, 2002, 166(1): 111-117. DOI: 10.1164/ajrccm.166.1.at1102
- [67] Minai OA, Gudavalli R, Mummadi S, et al. Heart rate recovery predicts clinical worsening in patients with pulmonary arterial hypertension[J]. *Am J Respir Crit Care Med*, 2012, 185(4): 400-408. DOI: 10.1164/rccm.201105-0848OC.
- [68] Guazzi M, Adams V, Conraads V, et al. EACPR / AHA scientific statement Clinical recommendations for cardiopulmonary exercise testing data assessment in specific patient populations[J]. *Circulation*, 2012, 126(18): 2261 - 2274. DOI: 10.1161/CIR.0b013e31826fb946
- [69] Sun XG, Hansen JE, Oudiz RJ, et al. Exercise pathophysiology in patients with primary pulmonary hypertension[J]. *Circulation*, 2001, 104(4): 429-435.
- [70] [J]. , 2013, 41(6): 497-500. DOI: 10.3760/cma.j.issn.0253-3758.2013.06.013
- [71] Zhang HD, Lv ZC, Wang LT, et al. Prognostic significance of reduced blood pressure response to exercise in pediatric pulmonary arterial hypertension[J]. *Am J Respir Crit Care Med*, 2017, 196(11): 1478-1481. DOI: 10.1164/rccm.201701-0131LE.
- [72] Hoeper MM, Pittrow D, Opitz C, et al. Risk assessment in pulmonary arterial hypertension[J]. *Eur Respir J*, 2018, 51(3): pii: 1702606. DOI: 10.1183/13993003.02606.2017.
- [73] Jais X, Olsson KM, Barbera JA, et al. Pregnancy outcomes in pulmonary arterial hypertension in the modern management era[J]. *Eur Respir J*, 2012, 40(4): 881 - 885. DOI: 10.1183/09031936.00141211.
- [74] Chan L, LMK C, Kennedy M, et al. Benefits of intensive treadmill exercise training on cardiorespiratory function and quality of life in patients with pulmonary hypertension[J]. *Chest*, 2013, 143(2): 333-343. DOI: 10.1378/chest.12-0993
- [75] Preston IR, Roberts KE, Miller DP, et al. Effect of warfarin treatment on survival of patients with pulmonary arterial hypertension (PAH) in the registry to evaluate early and long-term PAH disease management (REVEAL)[J]. *Circulation*, 2015, 132(25): 2403-2411. DOI: 10.1161/CIRCULATIONAHA.115.018435
- [76] Rhodes CJ, Howard LS, Busbridge M et al. Iron deficiency and raised hepcidin in idiopathic pulmonary arterial hypertension: clinical prevalence, outcomes, and mechanistic insights[J]. *J Am Coll Cardiol*, 2011, 58(3): 300 - 309. DOI: 10.1016/j.jacc.2011.02.057.
- [77] Giaid A, Yanagisawa M, Langleben D, et al. Expression of endothelin 1 in the lungs of patients with pulmonary hypertension [J]. *N Engl J Med*, 1993, 328(24): 1732-1739. DOI: 10.1056/NEJM199306173282402
- [78] Rubin LJ, Badesch DB, Barst RJ, et al. Bosentan therapy for pulmonary arterial hypertension[J]. *N Engl J Med*, 2002, 346(12): 896-903.
- [79] Jing ZC, Strange G, Zhu XY, et al. Efficacy, safety and tolerability of bosentan in Chinese patients with pulmonary arterial hypertension[J]. *J Heart Lung Transplant*, 2010, 29(2): 150-156. DOI: 10.1016/j.healun.2009.09.020
- [80] [J]. , 2016, 31(2): 206-208
- [81] [J]. , 2011, 39(2): 124-127. DOI: 10.3760/cma.j.issn.0253-3758.2011.02.008
- [82] Galie N, Olschewski H, Oudiz RJ, et al. Ambrisentan for the treatment of pulmonary arterial hypertension. Results of the ambrisentan in pulmonary arterial hypertension, randomized, doubleblind, placebo controlled, multicenter, efficacy (ARIES) study 1 and 2. *Circulation*, 2008, 117: 3010-3019.
- [83] [J]. , 2013, 41(6):

- therapy for pulmonary arterial hypertension[J]. *N Engl J Med*, 2005,353(20):2148-2157. DOI: 10.1056/NEJMoa050010.
- [87] Sastry BK, Narasimhan C, Reddy NK, et al. Clinical efficacy of sildenafil in primary pulmonary hypertension: a randomized, placebo-controlled, double-blind, crossover study [J]. *J Am Coll Cardiol*, 2004,43(7):1149-1153. DOI: 10.1016/j.jacc.2003.10.056.
- [88] Simonneau G, Rubin LJ, Galie N, et al. Addition of sildenafil to long-term intravenous epoprostenol therapy in patients with pulmonary arterial hypertension: a randomized trial[J]. *Ann Intern Med*, 2008,149(8):521-530.
- [89] Rubin LJ, Badesch DB, Fleming TR, et al. Long term treatment with sildenafil citrate in pulmonary arterial hypertension: the SUPER-2 study[J]. *Chest*, 2011,140(5):1274-1283. DOI: 10.1378/chest.10-0969.
- [90] Xu XQ, Jing ZC, Zhang JH, et al. The efficacy and safety of sildenafil in Chinese patients with pulmonary arterial hypertension[J]. *Hypertens Res*, 2009, 32(10): 911 - 915. DOI: 10.1038/hr.2009.113.
- [91] Xiong CM, Lu XL, Shan GL, et al. Oral sildenafil therapy for Chinese patients with pulmonary arterial hypertension: a multicenter study[J]. *J Clin Pharmacol*, 2012, 52(3): 425- 431. DOI: 10.1177/0091270011398241.
- [92] Zhang ZN, Jiang X, Zhang R, et al. Oral sildenafil treatment for Eisenmenger syndrome: a prospective, open label, multicentre study[J]. *Heart*, 2011,97(22):1876-1881. DOI: 10.1136/heartjnl-2011-300344.
- [93] Galie N, Brundage BH, Ghofrani HA, et al. Tadalafil therapy for pulmonary arterial hypertension[J]. *Circulation*, 2009, 119(22):2894-2903. DOI: 10.1161/CIRCULATIONAHA.108.839274.
- [94] Oudiz RJ, Brundage BH, Galie N, et al. Tadalafil for the treatment of pulmonary arterial hypertension: a double-blind 52-week uncontrolled extension study[J]. *J Am Coll Cardiol*, 2012,60(8):768-774. DOI: 10.1016/j.jacc.2012.05.004.
- [95] Jing ZC, Jiang X, Wu BX, et al. Vardenafil treatment for patients with pulmonary arterial hypertension: a multicentre, open-label study[J]. *Heart*, 2009, 95(18): 1531 - 1536. DOI: 10.1136/hrt.2009.169417.
- [96] Jing ZC, Yu ZX, Shen JY, et al. Vardenafil in pulmonary arterial hypertension: a randomized, double-blind, placebo-controlled study[J]. *Am J Respir Crit Care Med*, 2011,183(12): 1723-1729. DOI: 10.1164/rccm.201101-0093OC.
- [97] Ghofrani HA, Galie N, Grimminger F, et al. Riociguat for the treatment of pulmonary arterial hypertension[J]. *N Engl J Med*, 2013,369(4):330-340. DOI: 10.1056/NEJMoa1209655.
- [98] Rubin LJ, Galie N, Grimminger F, et al. Riociguat for the treatment of pulmonary arterial hypertension: a long term extension study (PATENT-2)[J]. *Eur Respir J*, 2015,45(5):1303-1313. DOI: 10.1183/09031936.00090614.
- [99] Humbert M, Coghlan JG, Ghofrani HA, et al. Riociguat for the treatment of pulmonary arterial hypertension associated with connective tissue disease: results from PATENT 1 and PATENT-2[J]. *Ann Rheum Dis*, 2017, 76(2): 422- 426. DOI: 10.1136/annrheumdis-2015-209087.
- [100] Lian TY, Jiang X, Jing ZC. Riociguat a soluble guanylate cyclase stimulator for the treatment of pulmonary hypertension [J]. *Drug Des Devel Ther*, 2017,11:1195-1207. DOI: 10.2147/DDDT.S117277.
- [101] Rubin LJ, Mendoza J, Hood M, et al. Treatment of primary pulmonary hypertension with continuous intravenous prostacyclin (epoprostenol). Results of a randomized trial[J]. *Ann Intern Med*, 1990,112(7):485-491.
- [102] Barst RJ, Rubin LJ, Long WA, et al. A comparison of continuous intravenous epoprostenol (prostacyclin) with conventional therapy for primary pulmonary hypertension[J]. *N Engl J Med*, 1996, 334(5):296-301. DOI: 10.1056/NEJM199602013340504.
- [103] Badesch DB, Tapson VF, McGoon MD, et al. Continuous intravenous epoprostenol for pulmonary hypertension due to the scleroderma spectrum of disease. A randomized, controlled trial [J]. *Ann Intern Med*, 2000,132(6):425-434.
- [104] Higenbottam T, Butt AY, McMahon A, et al. Long term intravenous prostaglandin (epoprostenol or iloprost) for treatment of severe pulmonary hypertension[J]. *Heart*, 1998,80(2):151-155.
- [105] [J]. , 2009, 29(11): 1013- 1015. DOI: 10.3760/cma.j.issn.0254-1416.2009.11.014.
- [106] [J]. , 2012, 40(10): 854-857. DOI: 10.3760/cma.j.issn.0253-3758.2012.10.011.
- [107] Jing ZC, Parikh K, Pulido T, et al. Efficacy and safety of oral treprostinil monotherapy for the treatment of pulmonary arterial hypertension: a randomized, controlled trial[J]. *Circulation*, 2013, 127(5):624-633. DOI: 10.1161/CIRCULATIONAHA.112.124388.
- [108] Tapson VF, Torres F, Kermeen F, et al. Oral treprostinil for the treatment of pulmonary arterial hypertension in patients on background endothelin receptor antagonist and / or phosphodiesterase type 5 inhibitor therapy (the FREEDOM-C study): a randomized controlled trial[J]. *Chest*, 2012, 142(6): 1383-1390. DOI: 10.1378/chest.11-2212.
- [109] Barst RJ, McGoon M, McLaughlin V, et al. Beraprost therapy for pulmonary arterial hypertension[J]. *J Am Coll Cardiol*, 2003,41(12):2119-2125.
- [110] Galie N, Humbert M, Vachiéry JL, et al. Effects of beraprost sodium, an oral prostacyclin analogue, in patients with pulmonary arterial hypertension: a randomized, double-blind, placebo-controlled trial [J]. *J Am Coll Cardiol*, 2002, 39(9):1496-1502.
- [111] Nagaya N, Uematsu M, Okano Y, et al. Effect of orally active prostacyclin analogue on survival of outpatients with primary pulmonary hypertension[J]. *J Am Coll Cardiol*, 1999, 34(4): 1188-1192.
- [112] Sitbon O, Channick R, Chin KM, et al. Selexipag for the treatment of pulmonary arterial hypertension[J]. *N Engl J Med*, 2015, 373(26):2522-2533. DOI: 10.1056/NEJMoa1503184.
- [113] Sitbon O, Gaine S. Beyond a single pathway: combination therapy in pulmonary arterial hypertension[J]. *Eur Respir Rev*, 2016, 25(142):408-417. DOI: 10.1183/16000617.0085-2016.
- [114] Kurzyna M, Dabrowski M, Bielecki D, et al. Atrial septostomy in treatment of end-stage right heart failure in patients with pulmonary hypertension[J]. *Chest*, 2007,131(4):977-983. DOI: 10.1378/chest.06-1227.
- [115] [J]. , 2015, 43(4): 319- 322. DOI: 10.3760/cma.j.issn.0253-3758.2015.04.008.
- [116] Rajeshkumar R, Pavithran S, Sivakumar K, et al. Atrial septostomy with a predefined diameter using a novel occlutech atrial flow regulator improves symptoms and cardiac index in patients with severe pulmonary arterial hypertension[J]. *Catheter Cardiovasc Interv*, 2017, 90(7): 1145- 1153. DOI: 10

- 1002/cod.27233.
- [117] Bartolome S, Hoeper MM, Klepetko W. Advanced pulmonary arterial hypertension: mechanical support and lung transplantation[J]. *Eur Respir Rev*, 2017, 26(146): pii170089. DOI:10.1183/16000617.0089.2017.
- [118] Weill D, Benden C, Corris PA, et al. A consensus document for the selection of lung transplant candidates: 2014-an update from the Pulmonary Transplantation Council of the International Society for Heart and Lung Transplantation[J]. *J Heart Lung Transplant*, 2015, 34(1): 1-15. DOI: 10.1016/j.healun.2014.06.014.
- [119] Tudorache I, Sommer W, Kühn C, et al. Lung transplantation for severe pulmonary hypertension-awake extracorporeal membrane oxygenation for postoperative left ventricular remodeling[J]. *Transplantation*, 2015, 99(2): 451-458. DOI: 10.1097/TP.0000000000000348.
- [120] Yusen RD, Edwards LB, Kucheryavaya AY, et al. The registry of the international society for heart and lung transplantation: thirty second official adult lung and heart-lung Transplantation report- 2015; focus theme: early graft failure[J]. *J Heart Lung Transplant*, 2015, 34(10): 1264-1277. DOI: 10.1016/j.healun.2015.08.014.
- [121] , 18 [J]. , 2016, 96(36): 2909-2911. DOI: 10.3760/cma.j.issn.0376-2491.2016.36.014.
- [122] Chen SL, Zhang FF, Xu J, et al. Pulmonary artery denervation to treat pulmonary arterial hypertension: the single center, prospective, first-in-man PADN-1 study (first-in-man pulmonary artery denervation for treatment of pulmonary artery hypertension)[J]. *J Am Coll Cardiol*, 2013, 62(12): 1092-1100. DOI: 10.1016/j.jacc.2013.05.075.
- [123] Liu C, Jiang XM, Zhang J, et al. Pulmonary artery denervation improves pulmonary arterial hypertension induced right ventricular dysfunction by modulating the local renin-angiotensin aldosterone system[J]. *BMC Cardiovasc Disord*, 2016, 16(1): 192. DOI: 10.1186/s12872-016-0366-4.
- [124] Hoeper MM, Galie N, Murali S, et al. Outcome after cardiopulmonary resuscitation in patients with pulmonary arterial hypertension[J]. *Am J Respir Crit Care Med*, 2002, 165(3): 341-344. DOI: 10.1164/ajrccm.165.3.200109.0130c.
- [125] Tongers J, Schwerdtfeger B, Klein G, et al. Incidence and clinical relevance of supraventricular tachyarrhythmias in pulmonary hypertension[J]. *160 . 0360 in in*

- hypertension[J]. *J Am Coll Cardiol*, 2010,56(9):715-720. DOI: 10.1016/j.jacc.2010.03.065.
- [147] Cjcs F, Dias BA, Cvp J, et al. The role of target therapies in schistosomiasis-associated pulmonary arterial hypertension[J]. *Chest*, 2012,141(4):923-928. DOI: 10.1378/chest.11-0483
- [148] Wang LD, Chen HG, Guo JG, et al. A strategy to control transmission of *Schistosoma japonicum* in China[J]. *N Engl J Med*, 2009,360(2):121-128. DOI: 10.1056/NEJMoa0800135.
- [149] Sitbon O, Lascoux-Combe C, Delfraissy JF, et al. Prevalence of HIV related pulmonary arterial hypertension in the current antiretroviral therapy era[J]. *Am J Respir Crit Care Med*, 2008, 177(1):108-113. DOI: 10.1164/ajrccm.200704-541OC.
- [150] Opravil M, Sereni D. Natural history of HIV associated pulmonary arterial hypertension: trends in the HAART era[J]. *AIDS*, 2008, 22 Suppl 3: S35 - 40. DOI: 10.1097/01.aids.0000327514.60879.47.
- [151] Degano B, Guillaume M, Savale L, et al. HIV associated pulmonary arterial hypertension: survival and prognostic factors in the modern therapeutic era[J]. *AIDS*, 2010,24(1):67-75. DOI: 10.1097/QAD.0b013e328331c65e.
- [152] Montani D, Price LC, Dorfmueller P, et al. Pulmonary veno-occlusive disease[J]. *Eur Respir J*, 2009, 33(1): 189-200. DOI: 10.1183/09031936.00090608.
- [153] , . : [J]. ,2018, 9(3):197-201. DOI: 10.3969/j.issn.1674-9081.2018.03.002
- [154

- [178] Moser KM, Bloor CM. Pulmonary vascular lesions occurring in patients with chronic major vessel thromboembolic pulmonary hypertension[J]. *Chest*, 1993,103(3):685-692
- [179] Auger WR, Kim NH, Trow TK. Chronic thromboembolic pulmonary hypertension[J]. *Clin Chest Med*, 2010,31(4): 741-758. DOI: 10.1016/j.ccm.2010.07.006
- [180] Wilkens H, Lang I, Behr J, et al. Chronic thromboembolic pulmonary hypertension (CTEPH): updated recommendations of the cologne consensus conference 2011[J]. *Int J Cardiol*, 2011, 154 Suppl 1: S54-60. DOI: 10.1016/S0167-5273(11)70493-4.
- [181] Jais X, D'Armini AM, Jansa P, et al. Bosentan for treatment of inoperable chronic thromboembolic pulmonary hypertension: BENEFIT (bosentan effects in inoperable forms of chronic thromboembolic pulmonary hypertension) study. *Int J Cardiol*, 2010, 130(1): 1-10. DOI: 10.1016/j.ijcard.2010.03.010

HR, /min		
BP, mmHg		
SVC mmHg		
RAP, mmHg		
RVP, mmHg		
PAP, mmHg		
PAWP, mmHg		
CO L/min		
CI L·min ⁻¹ ·m ⁻²		
PVR Wood		
TPR Wood		
SVR Wood		

ml				
		ml	ml/s	PSI

